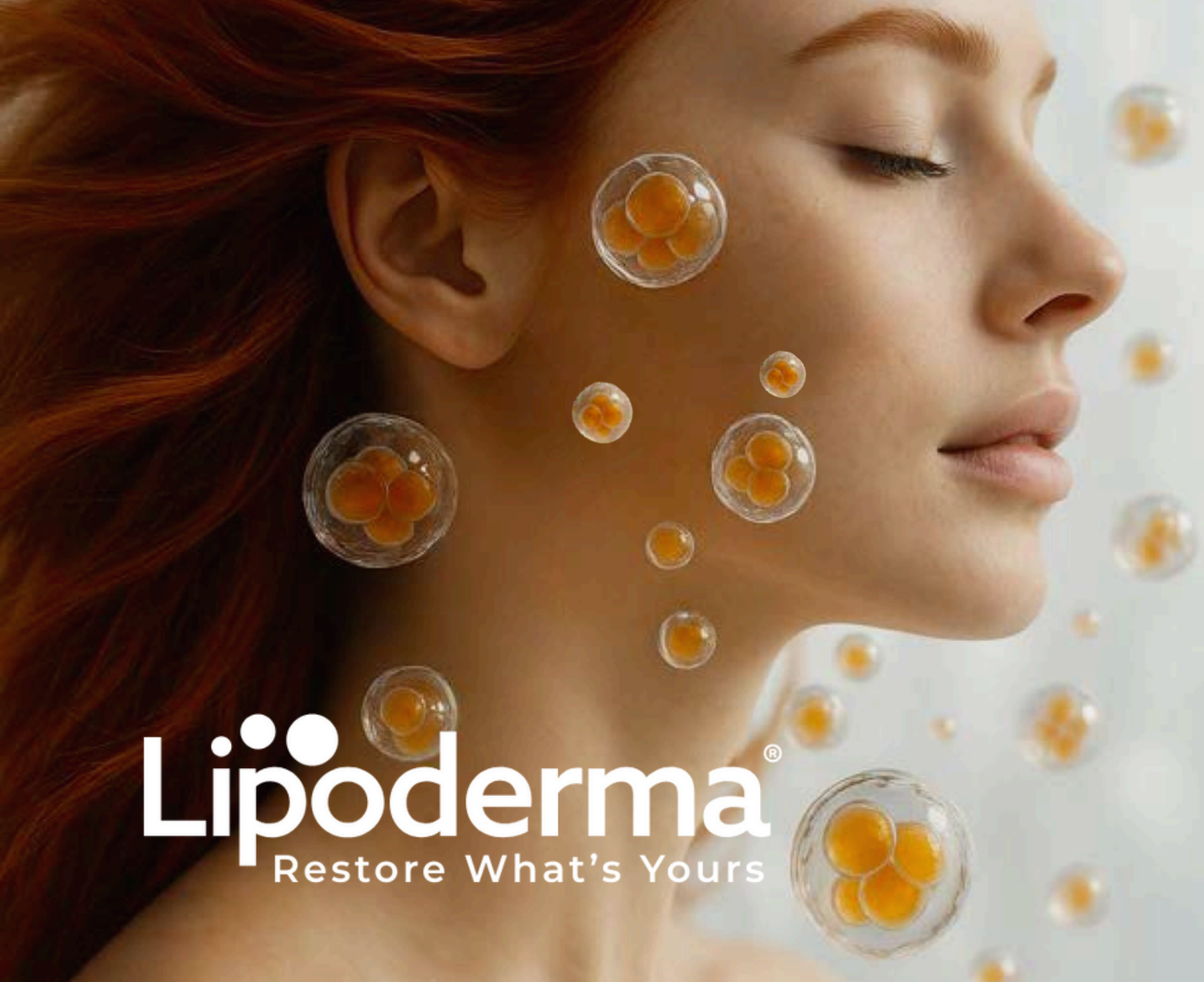



Lipoderma[®]
Restore What's Yours

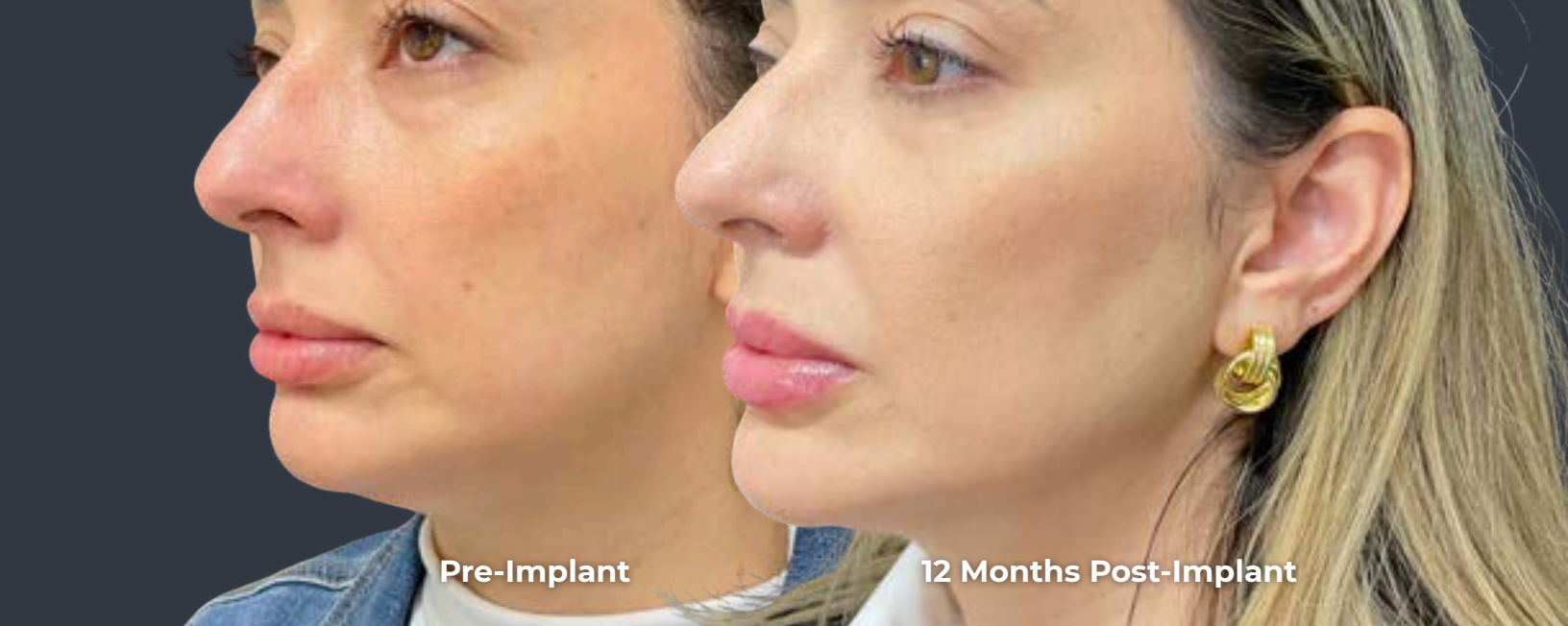Clinical Casebook

Britecyte[®]

4985 Winchester Blvd
Frederick, MD 21703

lipoderma.com
brighterlives@britecyte.com

LD-03



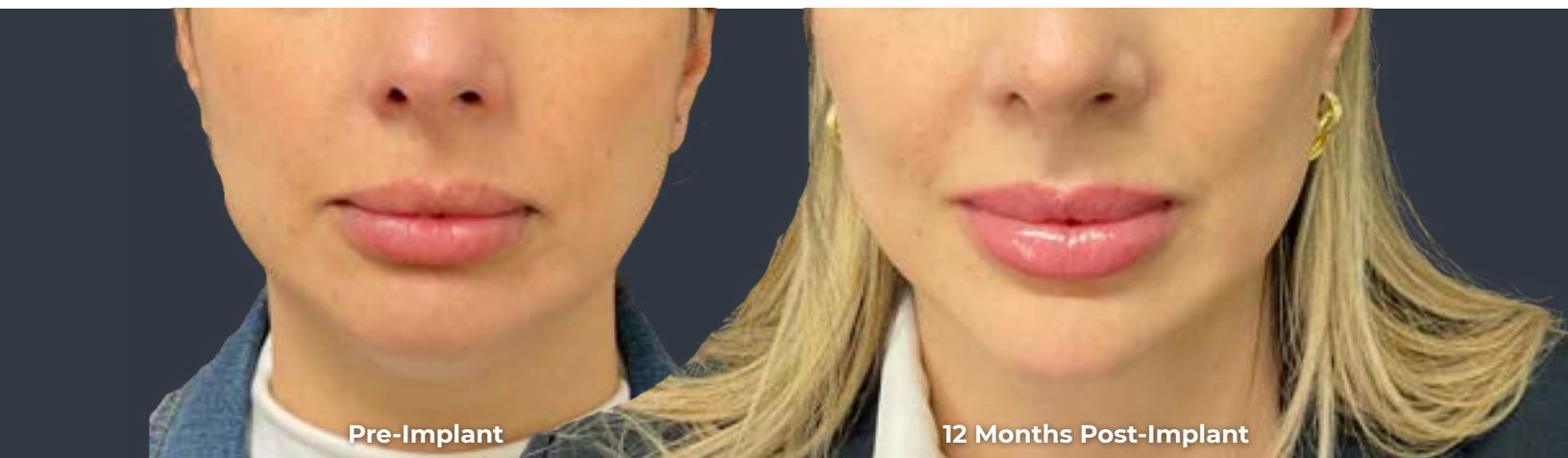
Pre-Implant

12 Months Post-Implant

FACIAL APPLICATION

CASE INFORMATION

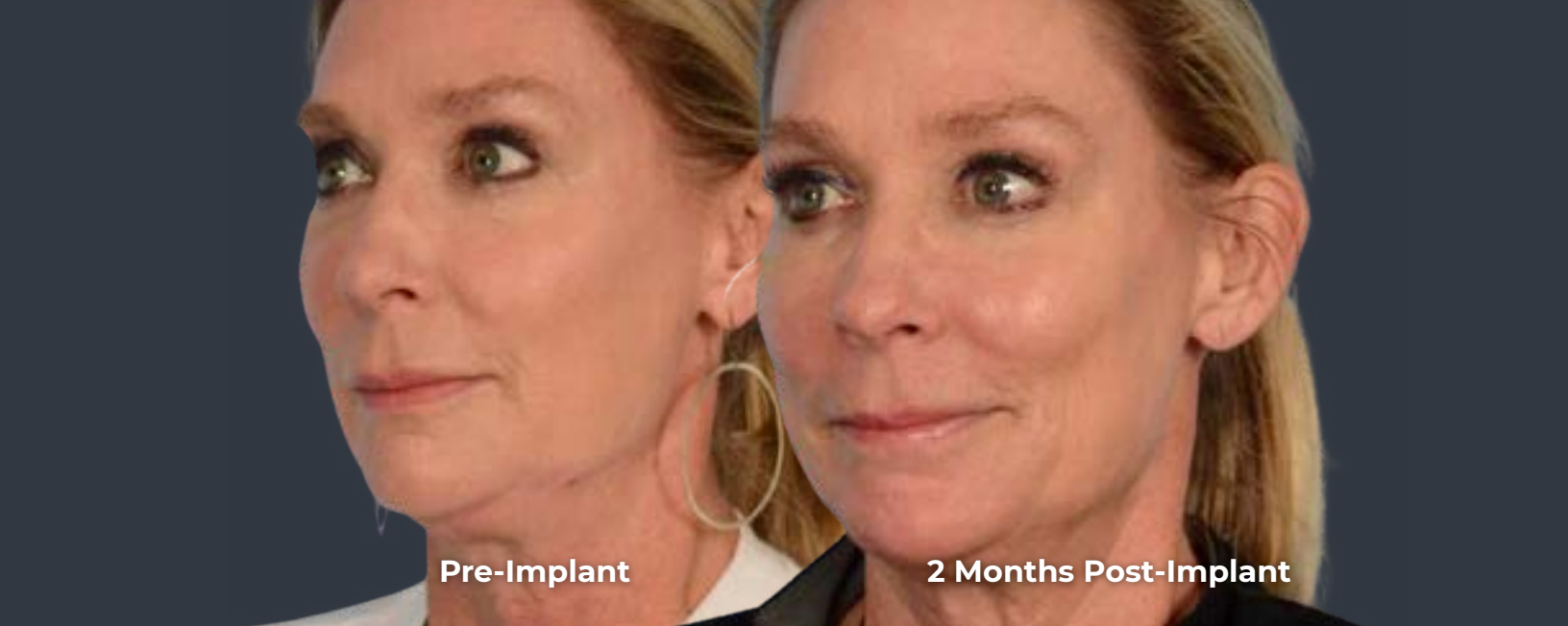- **Patient:** 36-year-old female
- **Indication:** Reduced facial fat pads and consequent skin sagging due to recent weight loss from GLP-1 use
- **Procedure Area:** 3.0 mL of Lipoderma was implanted along the mandible, and 1.5 mL was implanted in the zygomatic and mentum regions
- **Procedure Date:** September 17, 2024



Pre-Implant

12 Months Post-Implant

Photos courtesy of Michelle Beccio, FNP-BC



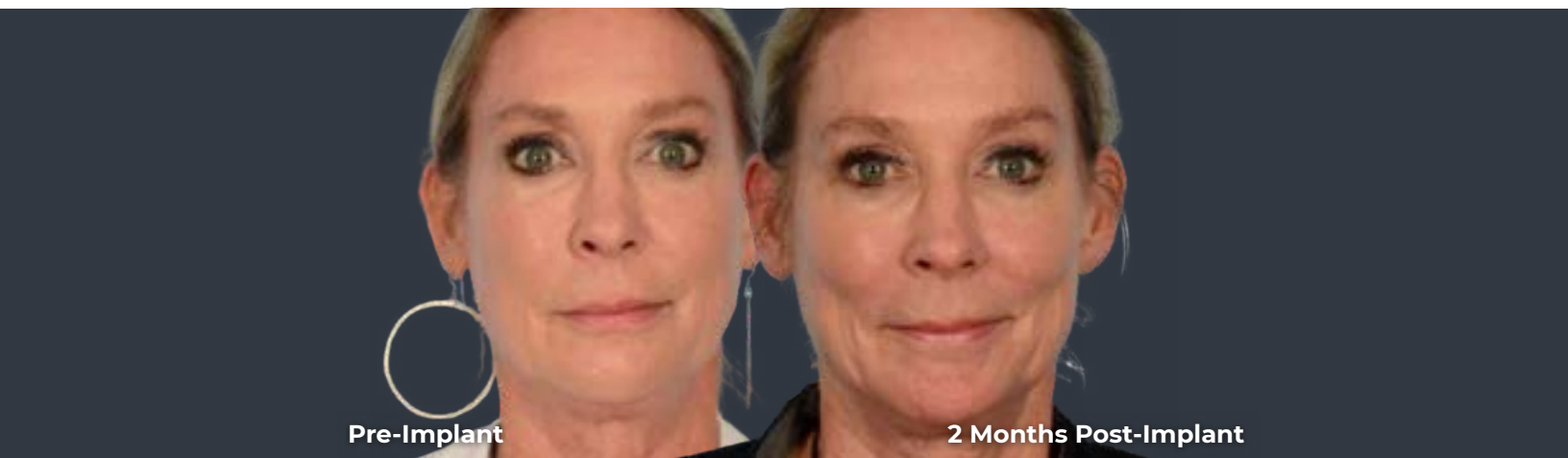Pre-Implant

2 Months Post-Implant

FACIAL APPLICATION

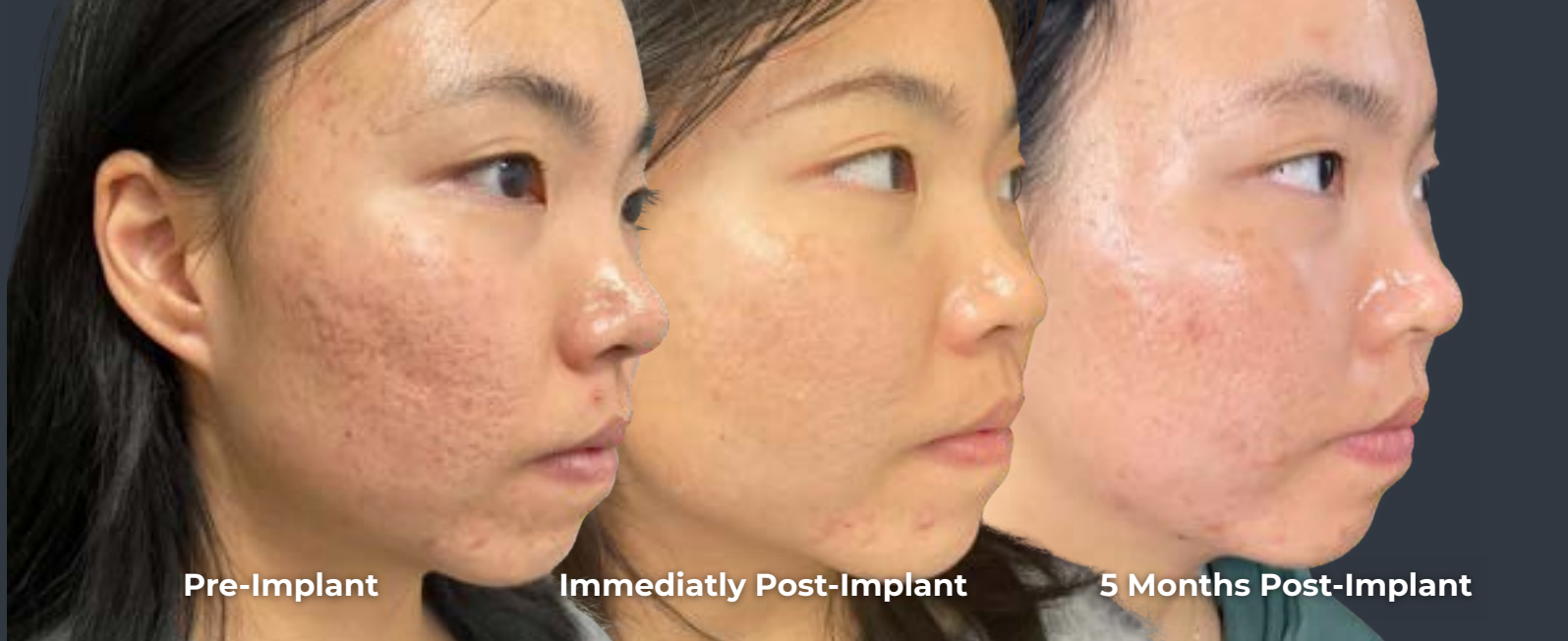CASE INFORMATION

- **Patient:** 60-year-old female
- **Indication:** Age-related fat pad loss
- **Procedure Area:** 7.5 mL of Lipoderma was implanted in the cheeks, nasolabial folds, pre-jowl sulcus, and oral commissures; one month later, 4.5 mL was implanted in the upper oral commissures
- **Procedure Date:** September 20, 2024



Pre-Implant

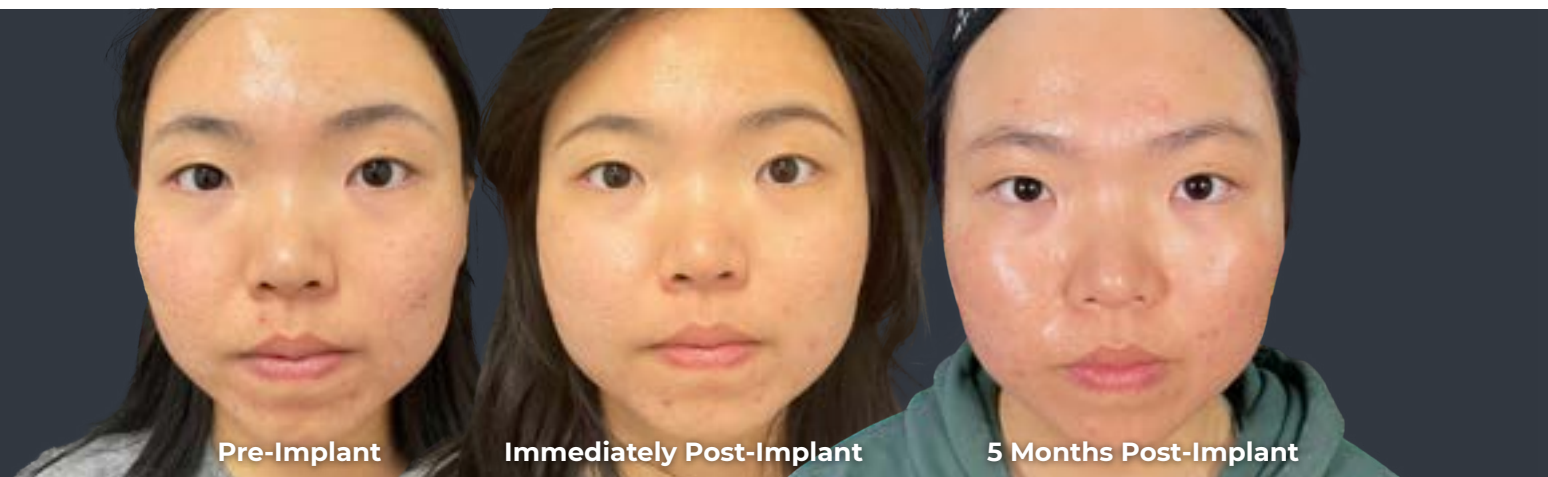2 Months Post-Implant



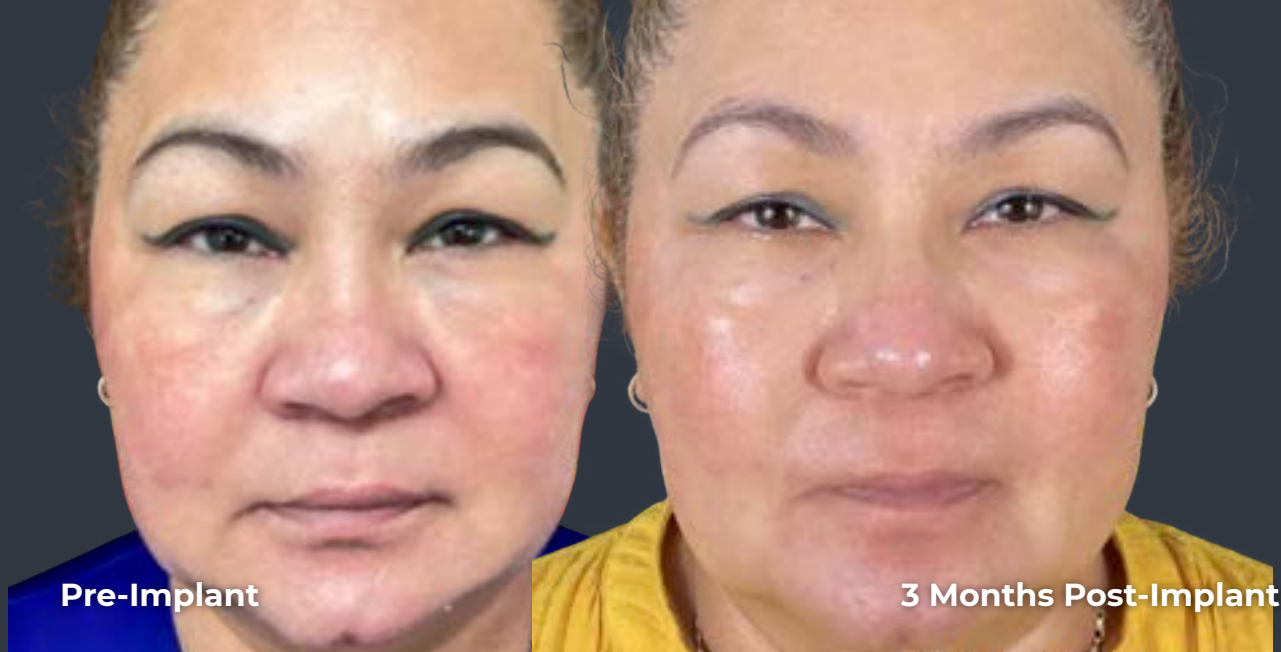FACIAL APPLICATION

CASE INFORMATION

- **Patient:** 22-year-old female
- **Indication:** Severe rolling and boxcar acne
- **Procedure Area:** 3.0 mL of Lipoderma was implanted bilaterally in the midface, targeting the malar and submalar regions
- **Procedure Date:** November 1, 2024



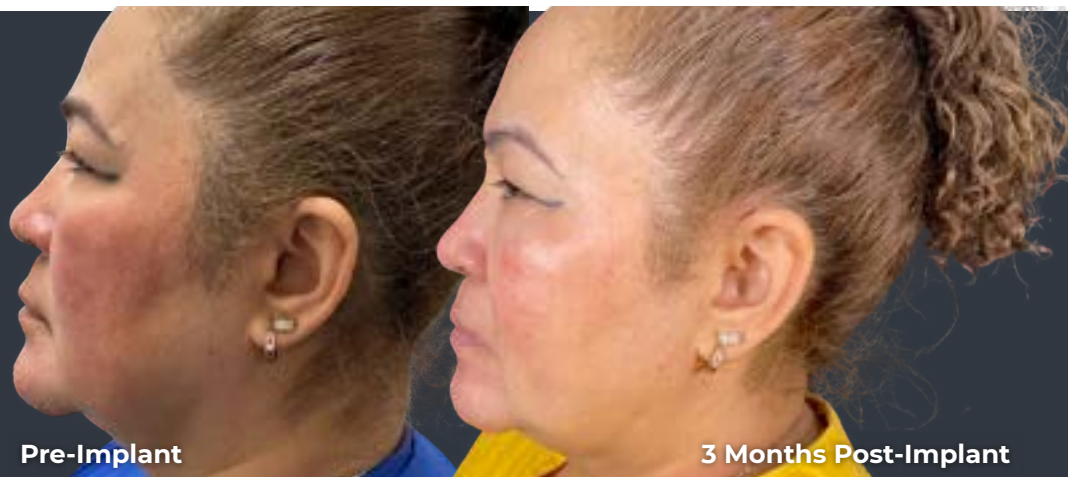Photos courtesy of Michelle Beccio, FNP-BC

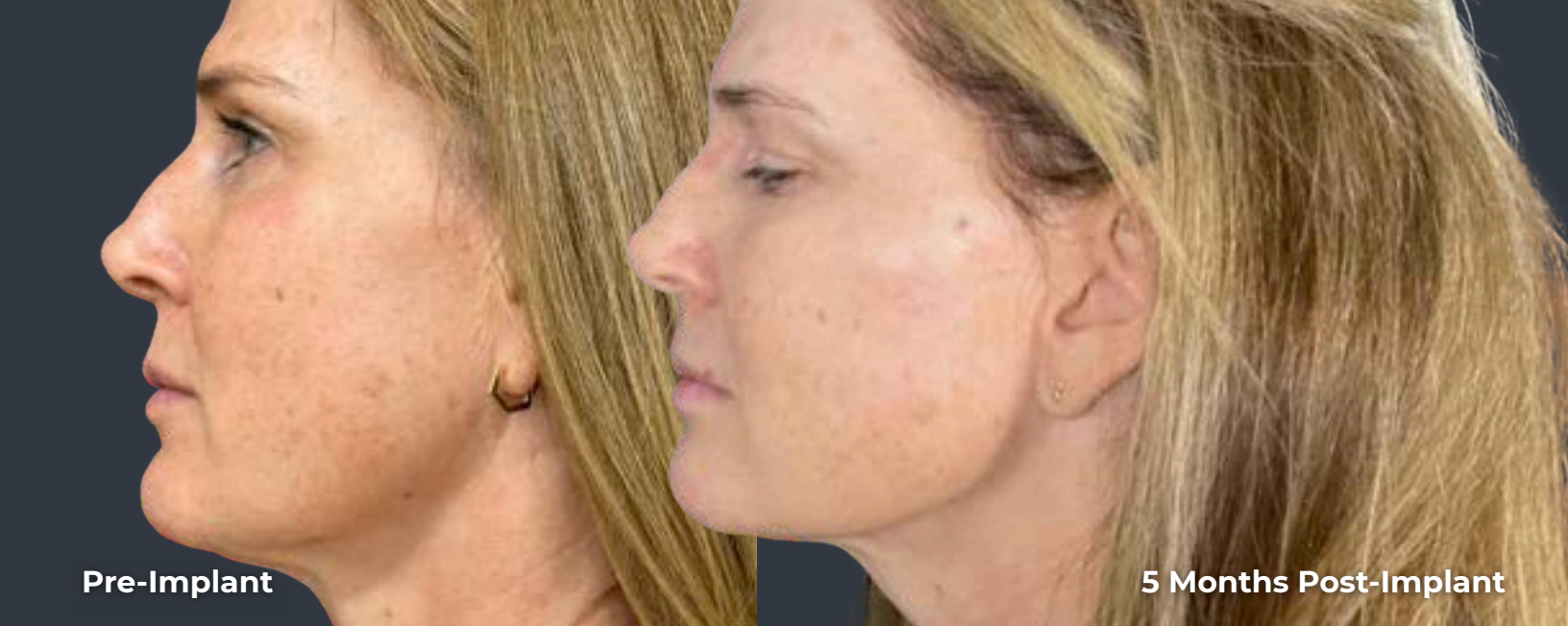

FACIAL APPLICATION

CASE INFORMATION

- **Patient:** 53-year-old female
- **Indication:** Age-related fat pad loss
- **Procedure Area:** 6.0 mL of Lipoderma was implanted into the mentum and jawline regions
- **Procedure Date:** November 26, 2024





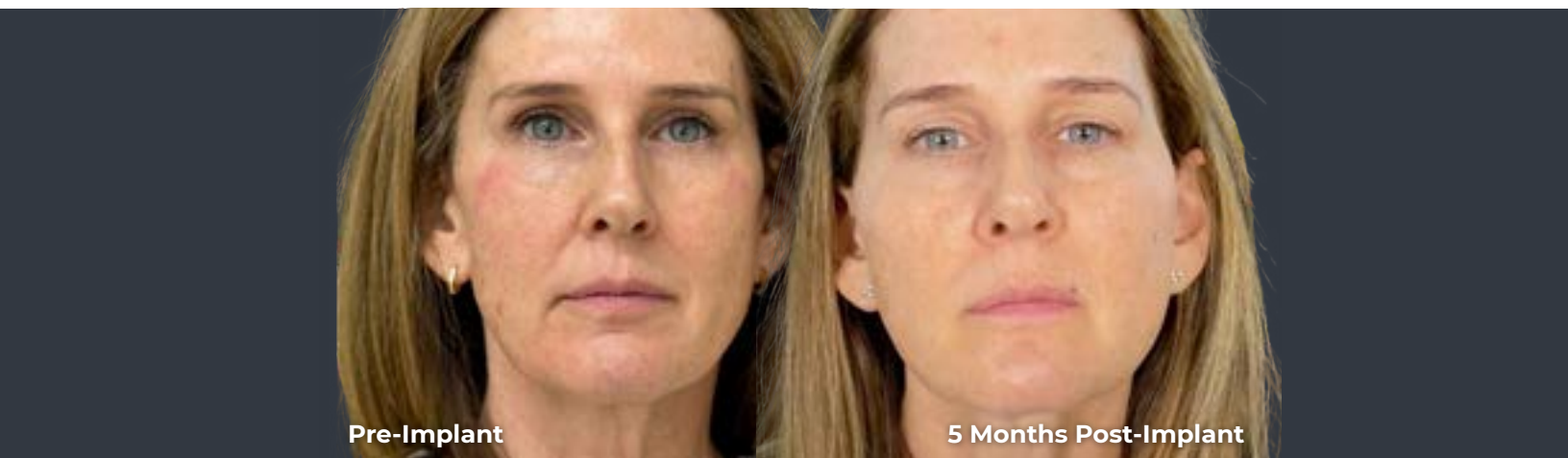Pre-Implant

5 Months Post-Implant

FACIAL APPLICATION

CASE INFORMATION

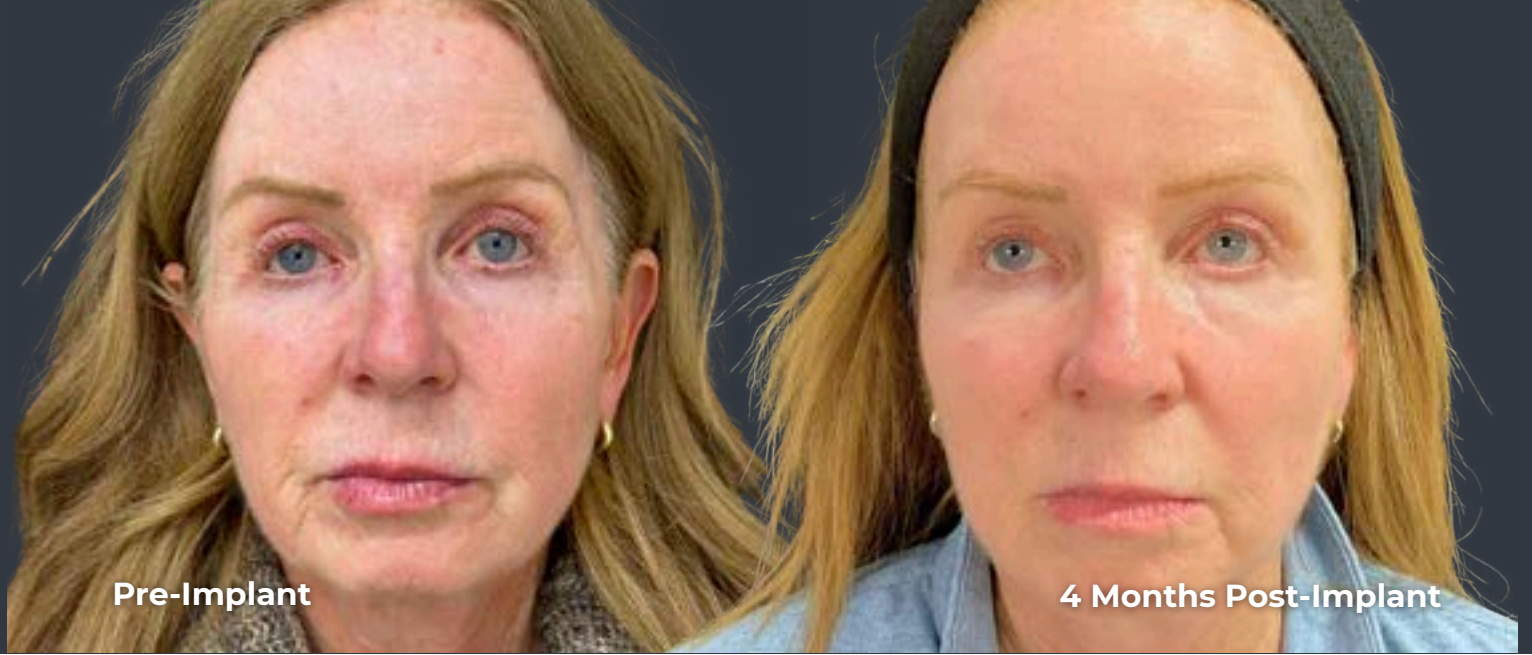- **Patient:** 54-year-old female
- **Indication:** Age-related fat pad loss, acne scar
- **Procedure Area:** 12.0 mL of Lipoderma was implanted in the temples, malar region, jawline, and areas of acne scarring; four months later, an additional 3.0 mL was implanted
- **Procedure Date:** December 10, 2024



Pre-Implant

5 Months Post-Implant

Photos courtesy of Michelle Beccio, FNP-BC



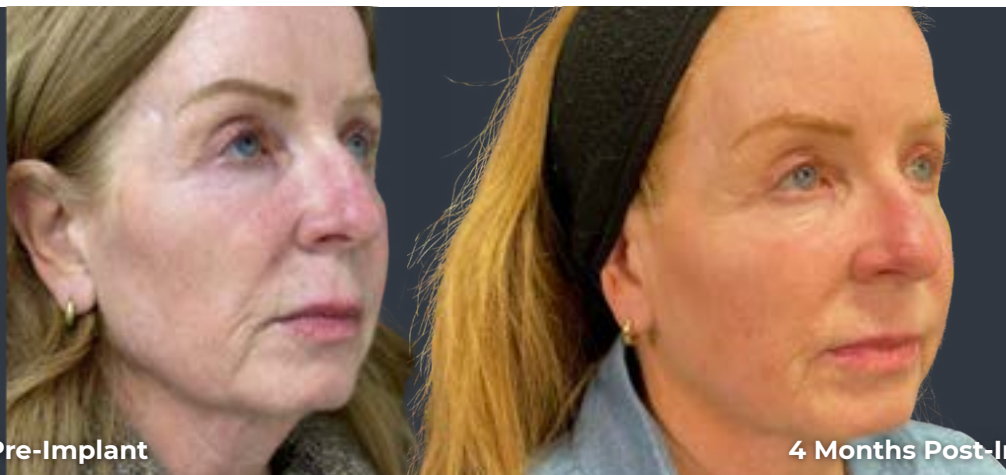Pre-Implant

4 Months Post-Implant

FACIAL APPLICATION

CASE INFORMATION

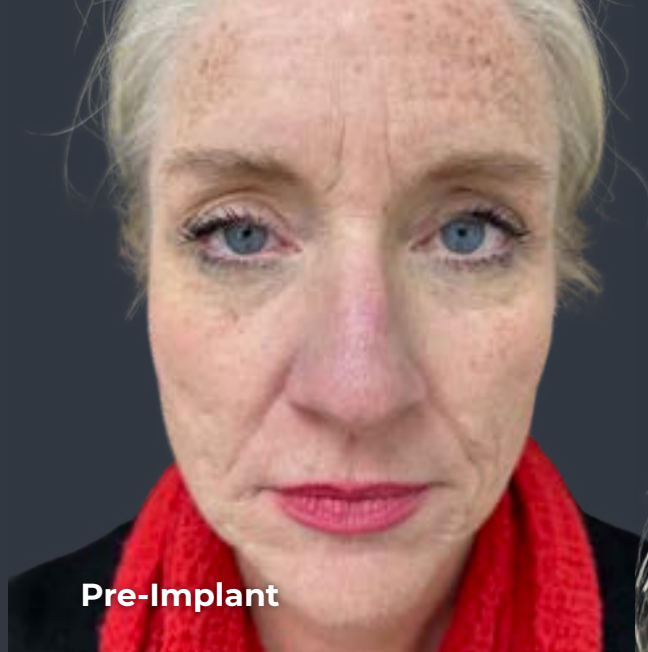- **Patient:** 53-year-old female
- **Indication:** Age-related fat pad loss
- **Procedure Area:** 7.5 mL of Lipoderma was implanted in the temples and midface region; three months later, an additional 6.0 mL was implanted
- **Procedure Date:** December 10, 2024



Pre-Implant

4 Months Post-Implant

Photos courtesy of Michelle Beccio, FNP-BC



Pre-Implant

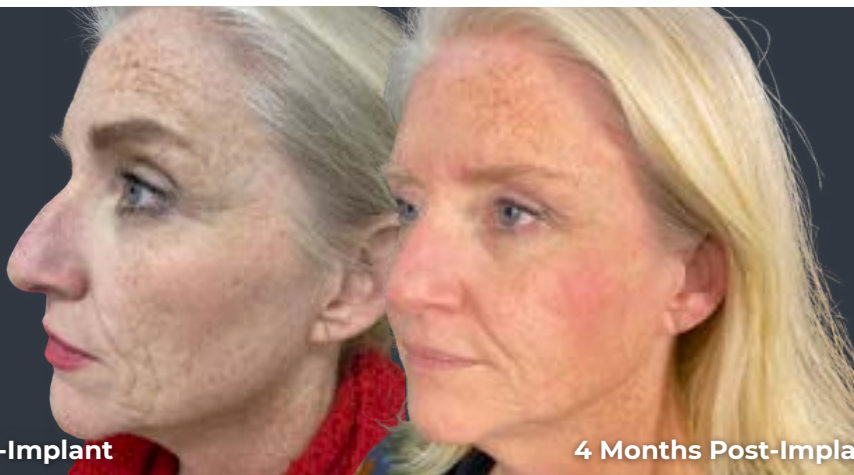

4 Months Post-Implant

FACIAL APPLICATION

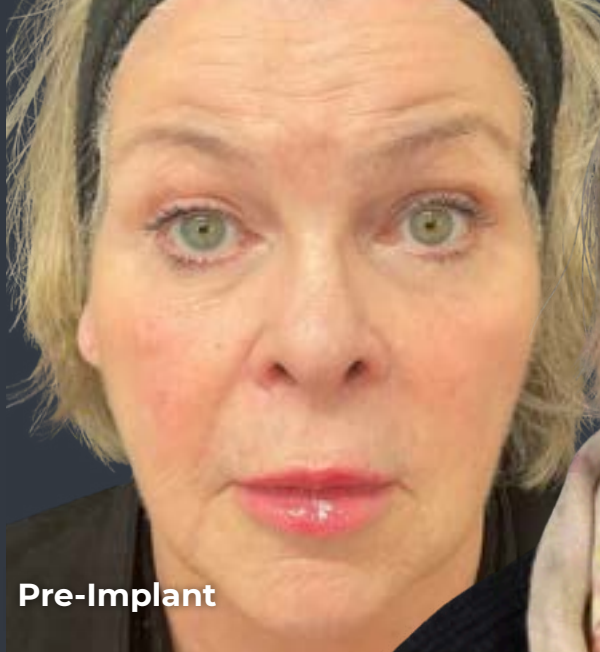CASE INFORMATION

- **Patient:** 54-year-old female
- **Indication:** Age-related fat pad loss
- **Procedure Area:** 6.0 mL of Lipoderma was implanted in the temples and midface region; four months later, an additional 6.0 mL was implanted
- **Procedure Date:** December 10, 2024



Pre-Implant

4 Months Post-Implant



Pre-Implant

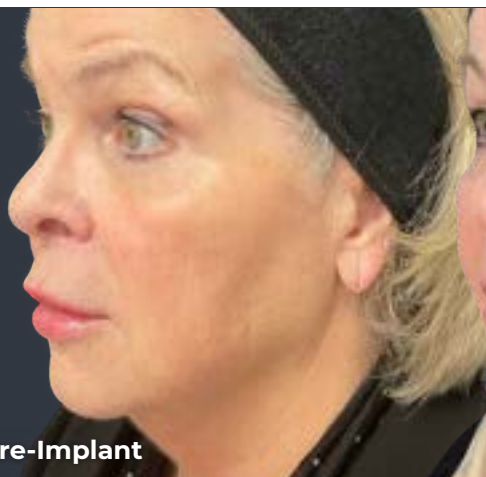


4 Months Post-Implant

FACIAL APPLICATION

CASE INFORMATION

- **Patient:** 60-year-old female
- **Indication:** Age-related fat pad loss
- **Procedure Area:** 6.0 mL of Lipoderma was implanted in the temples and malar region; four months later, an additional 6.0 mL was implanted
- **Procedure Date:** December 17, 2024



Pre-Implant



4 Months Post-Implant



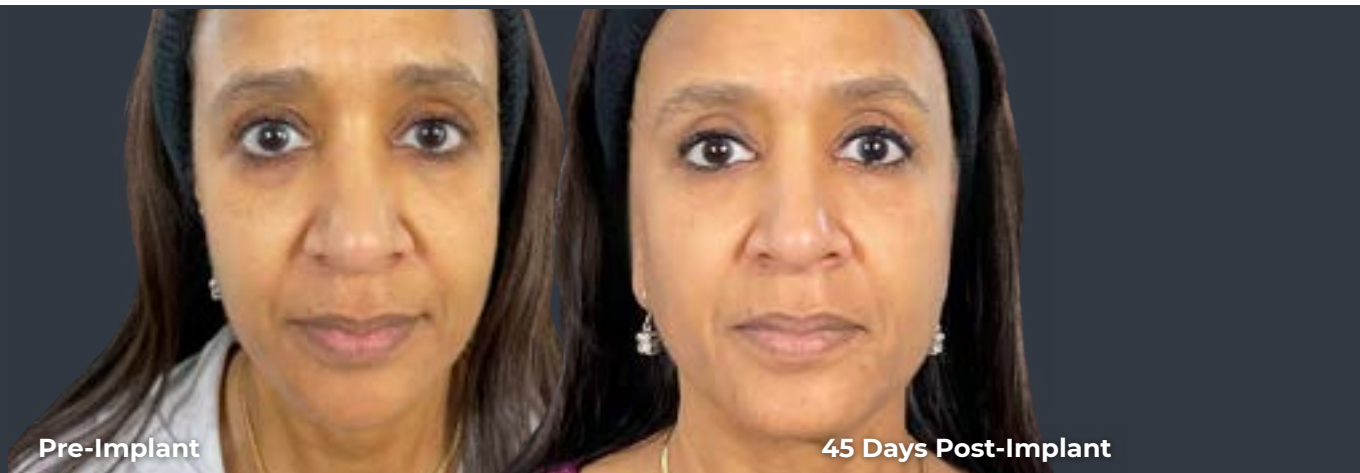Pre-Implant

45 Days Post-Implant

FACIAL APPLICATION

CASE INFORMATION


- **Patient:** 53-year-old female
- **Indication:** Age-related fat pad loss
- **Procedure Area:** 15.0 mL of Lipoderma was implanted in the midface and jawline
- **Procedure Date:** February 4, 2025



Pre-Implant

45 Days Post-Implant

Photos courtesy of Michelle Beccio, FNP-BC



Pre-Implant



45 Days Post-Implant

FACIAL APPLICATION

CASE INFORMATION

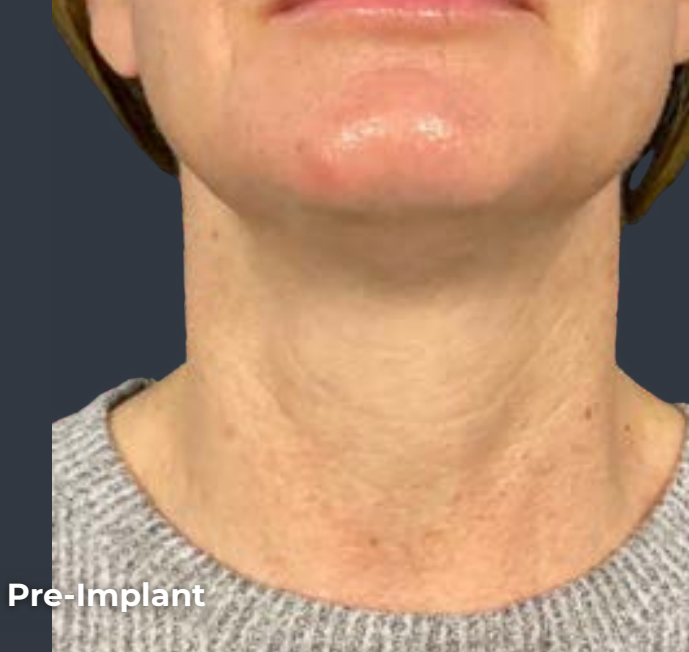- **Patient:** 44-year-old female
- **Indication:** Under eye hollowing, mid-temple hollowing
- **Procedure Area:** 1.5 mL of Lipoderma was implanted into each temple, and 4.5 mL on the left infraorbital hollow and 3.75 mL on the right infraorbital hollow
- **Procedure Date:** June 23, 2025



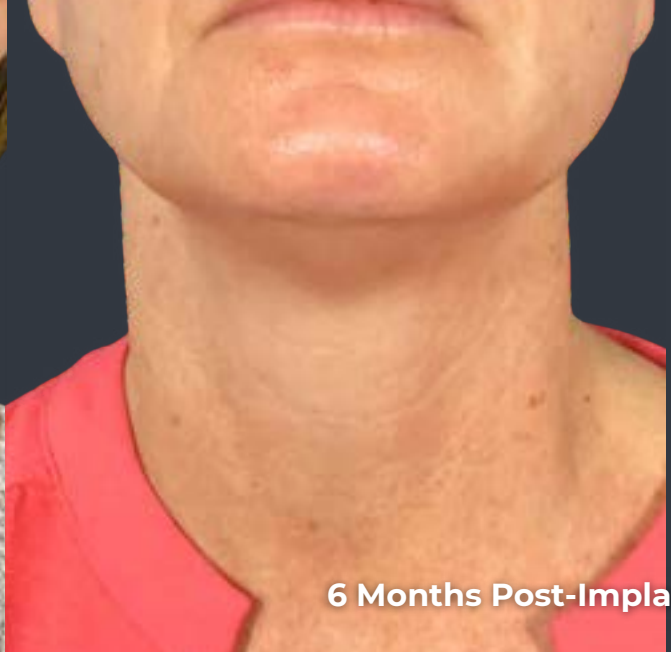Pre-Implant



45 Days Post-Implant



Pre-Implant

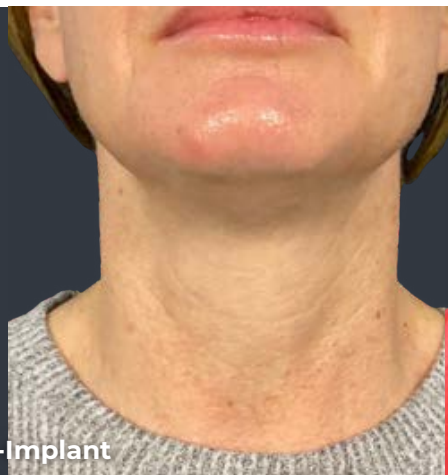

6 Months Post-Implant

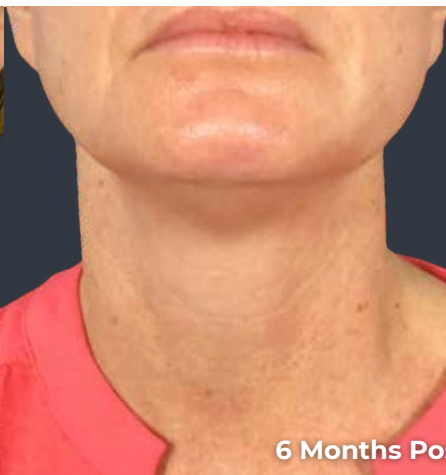FACIAL APPLICATION

CASE INFORMATION

- **Patient:** 53-year-old female
- **Indication:** Age-related fat pad loss in neck region
- **Procedure Area:** 3.0 mL of Lipoderma was implanted into the neck region; one month later, an additional 3.0 mL was implanted
- **Procedure Date:** March 5, 2025

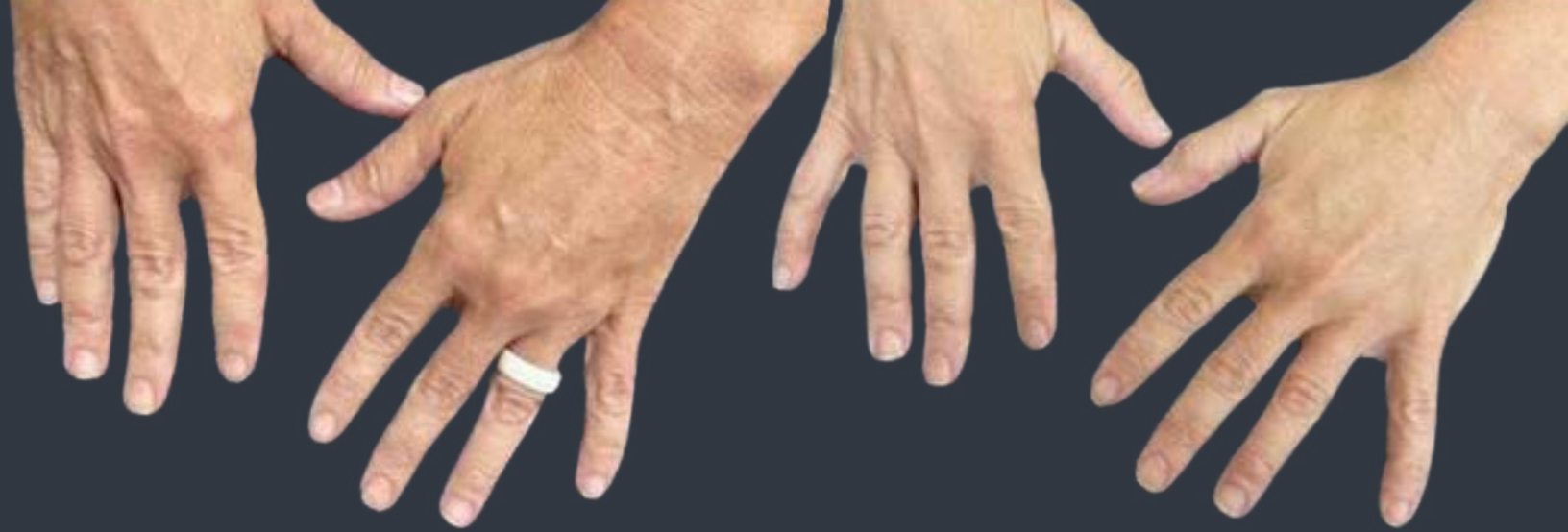

Pre-Implant



6 Months Post-Implant

Photos courtesy of Michelle Beccio, FNP-BC



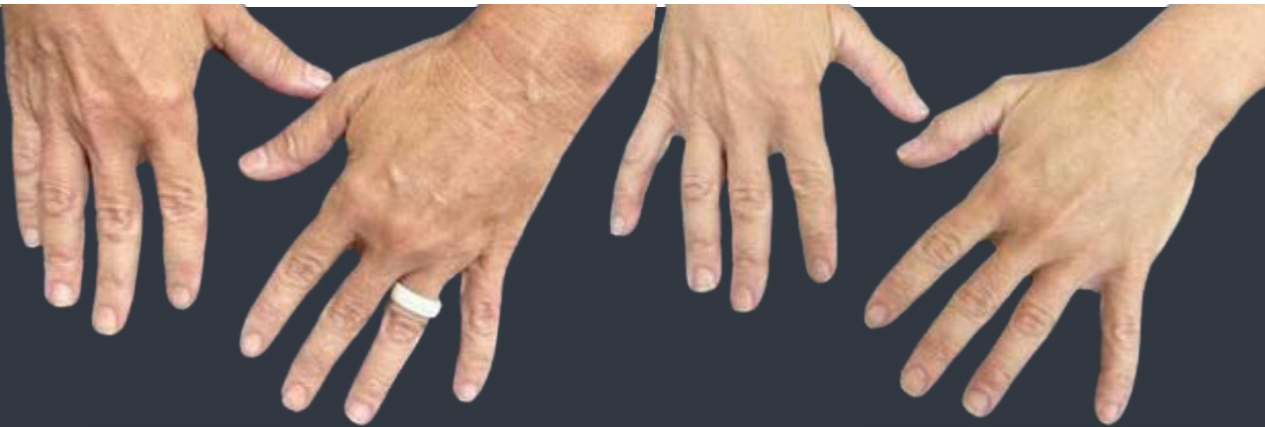Pre-Implant

2 Months Post-Implant

HAND APPLICATION

CASE INFORMATION

- **Patient:** 41-year-old female
- **Indication:** Volume loss in hands due to aging
- **Procedure Area:** 2.25 mL of Lipoderma was implanted into each hand for a total of 4.5 mL
- **Procedure Date:** July 24, 2025



Pre-Implant

2 Months Post-Implant

A photograph of a male patient's abdomen before the procedure. A white arrow points to a large, irregular scar on the upper right side of the abdomen.

Pre-Implant


A photograph of the same male patient's abdomen five months after the procedure. A white arrow points to the same area, showing a significantly smoother and more defined abdominal wall.

5 Months Post-Implant


ABDOMINAL APPLICATION

CASE INFORMATION

- **Patient:** 49-year-old male
- **Indication:** Emergency washout surgery for bowel obstruction with resulting dehiscence
- **Procedure Area:** 6.0 mL of Lipoderma was implanted following subcision of scar tissue
- **Procedure Date:** August 30, 2024

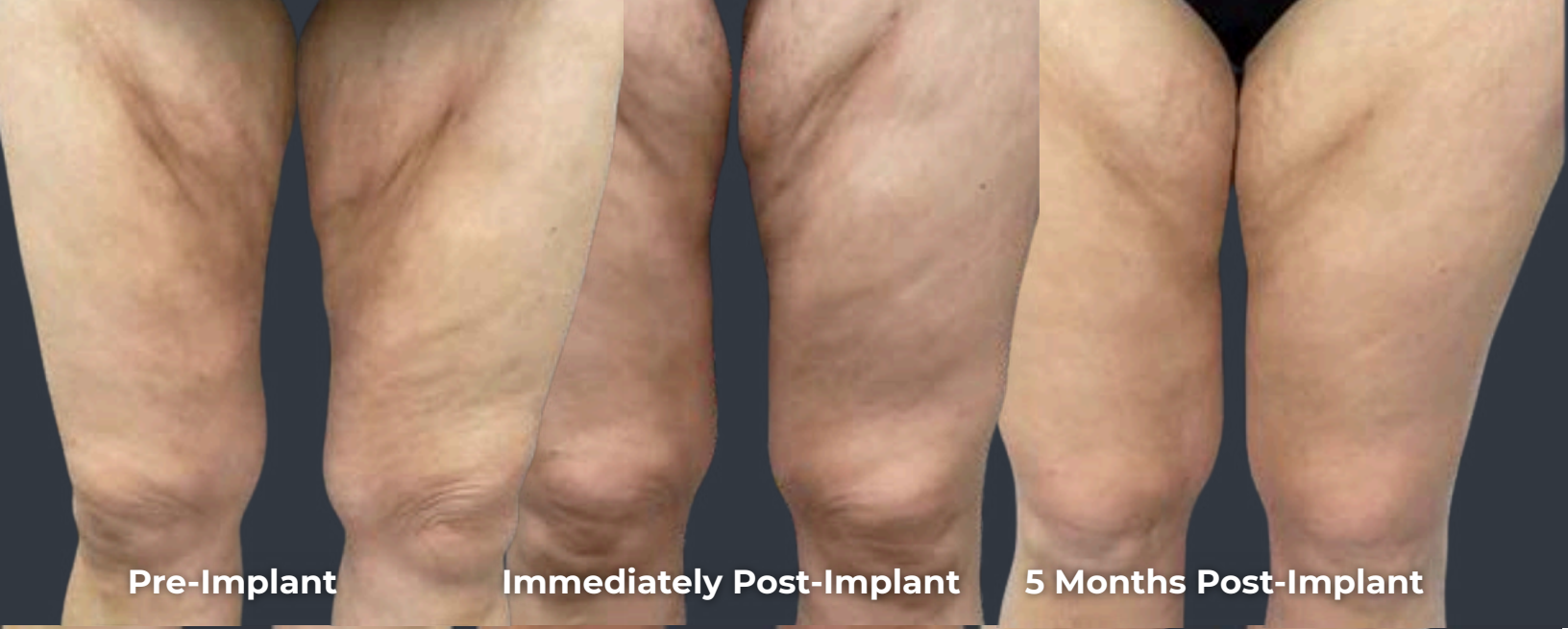A photograph of a male patient's abdomen before the procedure. A white arrow points to a large, irregular scar on the upper right side of the abdomen.

Pre-Implant

A photograph of the same male patient's abdomen five months after the procedure. A white arrow points to the same area, showing a significantly smoother and more defined abdominal wall.

5 Months Post-Implant

Photos courtesy of Michelle Beccio, FNP-BC



Pre-Implant

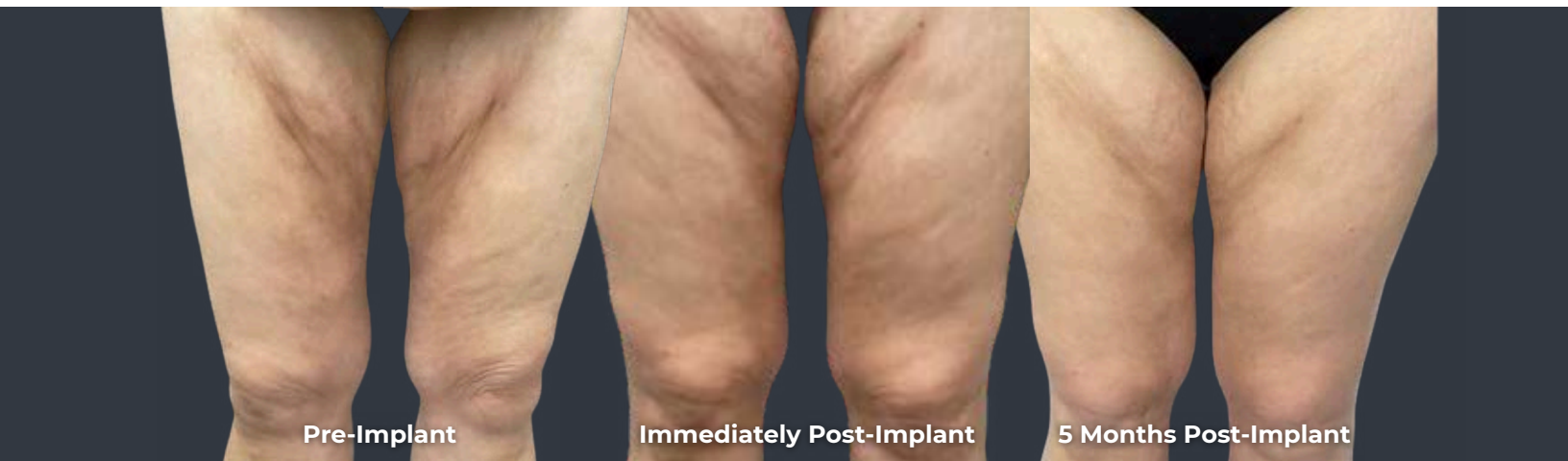Immediately Post-Implant

5 Months Post-Implant

THIGH APPLICATION

CASE INFORMATION

- **Patient:** 62-year-old female
- **Indication:** Liposuction 20 years ago resulting in tissue asymmetry of the inner thighs
- **Procedure Area:** 15.0 mL of Lipoderma was bilaterally implanted in the anterior thighs; two days later, an additional 3.0 mL was implanted using the same entry points
- **Procedure Date:** October 30, 2024

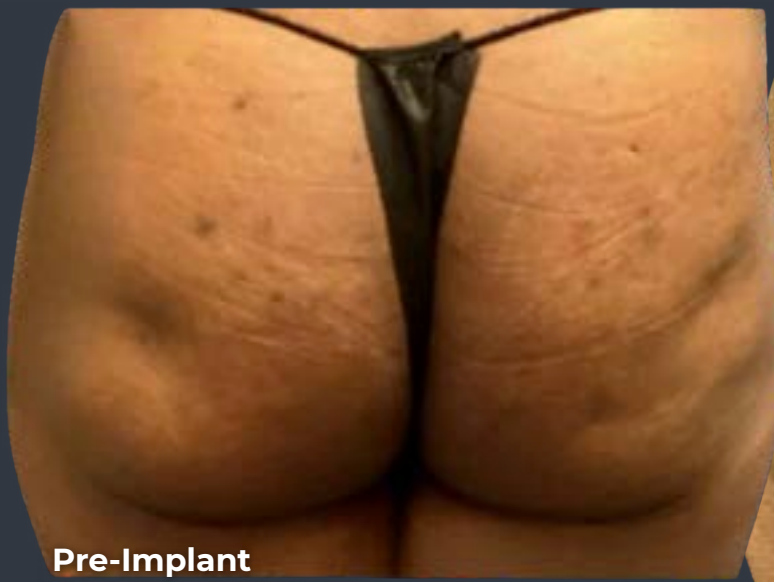

Pre-Implant

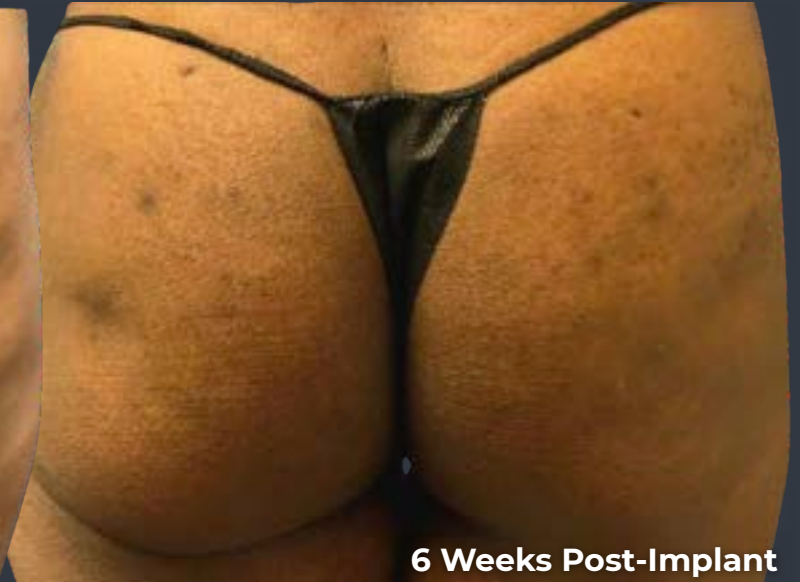Immediately Post-Implant

5 Months Post-Implant

Photos courtesy of Michelle Beccio, FNP-BC



Pre-Implant

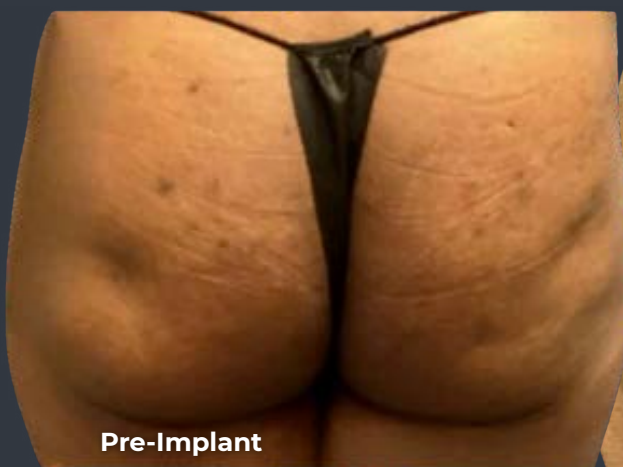

6 Weeks Post-Implant

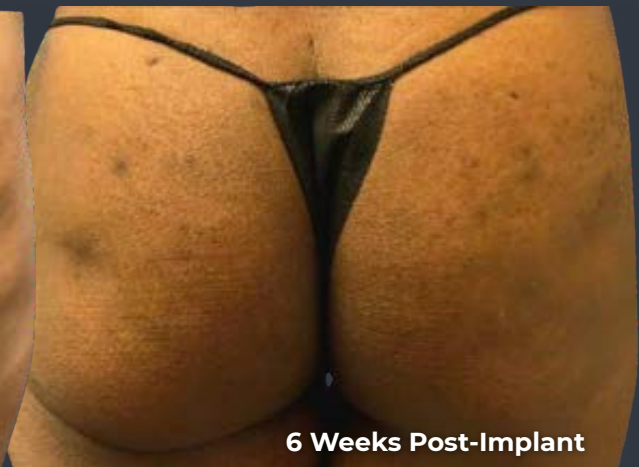BUTTOCK APPLICATION

CASE INFORMATION

- **Patient:** Female of unknown age
- **Indication:** Cellulite dimpling
- **Procedure Area:** 6.0 mL of Lipoderma was implanted into the right buttock in the area of dimpling
- **Procedure Date:** April 25, 2025



Pre-Implant



6 Weeks Post-Implant

Photos courtesy of Regina Fearmonti, MD



Pre-Implant



3 Months Post-Implant

HIP DIP APPLICATION

CASE INFORMATION

- **Patient:** 26-year-old female
- **Indication:** Distinguishable hip dips
- **Procedure Area:** 15.0 mL of Lipoderma was implanted into each hip region
- **Procedure Date:** August 14, 2025



Pre-Implant



3 Months Post-Implant